

# Severe Anterior Open-Bite Malocclusion

## *Orthognathic Surgery or Several Years of Orthodontics?*

Julio Pedra e Cal-Neto<sup>a</sup>; Cátia C. Quintão<sup>b</sup>; Luciane Macedo de Menezes<sup>c</sup>;  
Marco Antonio Almeida<sup>d</sup>

### ABSTRACT

This case report describes the treatment of a severe anterior open bite, Class II malocclusion with a history of dummy sucking. The 9-year-old girl presented with a significant anteroposterior and vertical discrepancy. Her face was convex with procumbent lips. She had an anterior open bite of 9 mm, an overjet of 8 mm, and a transverse maxillary deficiency. In consultation with the parents and patient, a nonsurgical therapy was elected, with the goals of reducing protrusion and closing the anterior open bite.

**KEY WORDS:** Anterior open bite; Transverse maxillary deficiency; Vertical excess

### INTRODUCTION

An anterior open bite is a lack of contact in a vertical direction between the incisal edges of the maxillary and mandibular anterior teeth.<sup>1</sup> Numerous theories of open-bite etiology have been proposed, including unfavorable growth patterns, heredity, digital habits, and tongue function.<sup>2</sup> Among the treatments used are habit-breaking appliances, bite blocks, high-pull headgear therapy, vertical-pull chin cups, vertical elastics, multiloop edgewise archwire therapy, and surgical correction.<sup>3-6</sup>

The following case report illustrates the treatment of a Class II malocclusion complicated by a dentoalveolar protrusion, an anterior open bite of 9 mm, and a Class II skeletal pattern.

### History and etiology

The patient was a 9-year, 8-month-old girl who sought care at the Orthodontic Clinic of the State University of Rio de Janeiro. Her chief complaint was an anterior open bite with an associated chewing problem. Her medical and dental history was noncontributory. She had a history of dummy sucking, allergic rhinitis, and swollen palatine tonsils. The enlarged tonsils were believed to have caused mouth breathing and compensatory anterior tongue posturing to achieve an adequate airway.

### Diagnosis

The patient had a Class II malocclusion with a 9-mm anterior open bite, 8-mm overjet, and no midline deviation (Figures 1-3). A space analysis indicated 0.5 mm of spacing in the maxillary arch and 2 mm of crowding in the mandibular arch. Furthermore, a convex profile because of a maxillary excess and a transverse maxillary deficiency was noted. She also demonstrated an acute nasolabial angle, an increased lower facial height, and strained circumoral musculature on lip closure.

Cephalometric analysis showed a skeletal Class II relationship (ANB 6°) with maxillary protrusion (SNA 88°), an increased steepness to her mandibular plane (FMA 30°; SN-GoGn 36°), and protrusive incisors (interincisal angle, 113°; maxillary incisor to NA angle, 32°; maxillary incisor to NA distance, 8 mm; mandibular incisor to NB angle, 28°; mandibular incisor to NB distance, 5.5 mm) (Figure 4). These findings were con-

<sup>a</sup> Graduate Student, Department of Orthodontics, State University of Rio de Janeiro, Rio de Janeiro, Brazil.

<sup>b</sup> Professor, Department of Orthodontics, State University of Rio de Janeiro, Rio de Janeiro, Brazil.

<sup>c</sup> Professor, Department of Orthodontics, PUCRS, Porto Alegre, Rio Grande do Sul, Brazil.

<sup>d</sup> Professor and Department Chair, Department of Orthodontics, State University of Rio de Janeiro, Rio de Janeiro, Brazil.

Corresponding author: Julio Pedra e Cal-Neto, DDS, MSc, Department of Orthodontics, State University of Rio de Janeiro, Rua Luis Belart 190/206, Jardim Guanabara, Rio de Janeiro, Rio de Janeiro 21941-100 Brazil (e-mail: juliocalneto@yahoo.com.br)

Accepted: July 2005. Submitted: March 2005.

© 2006 by The EH Angle Education and Research Foundation, Inc.

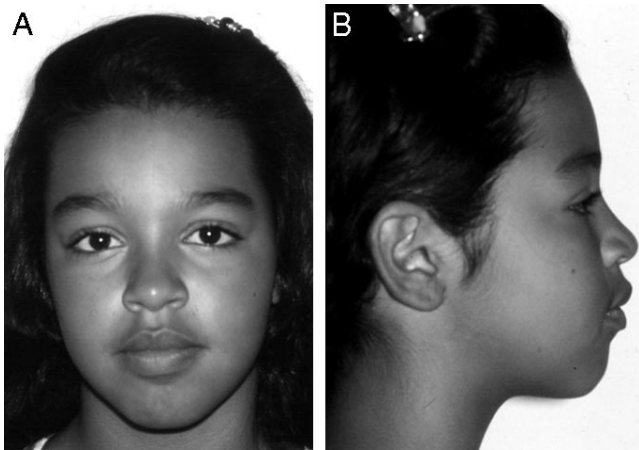


FIGURE 1. Pretreatment facial photographs.

sistent with the diagnosis of a Class II malocclusion with an anterior open bite secondary to a sucking habit.

**Treatment objectives**

The primary objective of treatment was to close the anterior open bite and attain a Class I canine and molar relationship with ideal overjet and overbite while improving facial esthetics. The complementary treatment objectives were to: (1) avoid extrusion of the molars and clockwise rotation of the mandible during treatment; (2) restrict maxillary vertical growth; (3) correct axial inclinations of maxillary and mandibular anterior teeth; (4) enhance facial profile and lip closure; (5) establish good functional occlusion; and (6) improve smile characteristics and dental esthetics.

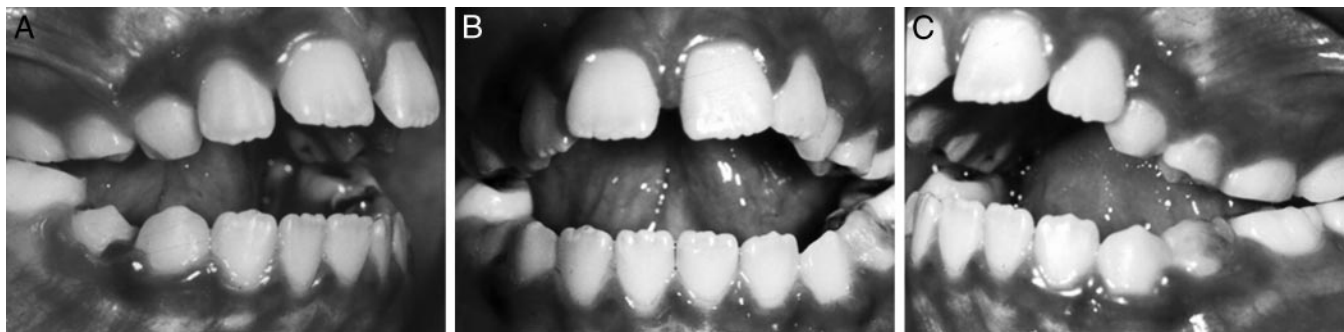

FIGURE 2. Pretreatment intraoral photographs showing a negative overbite of 10 mm.

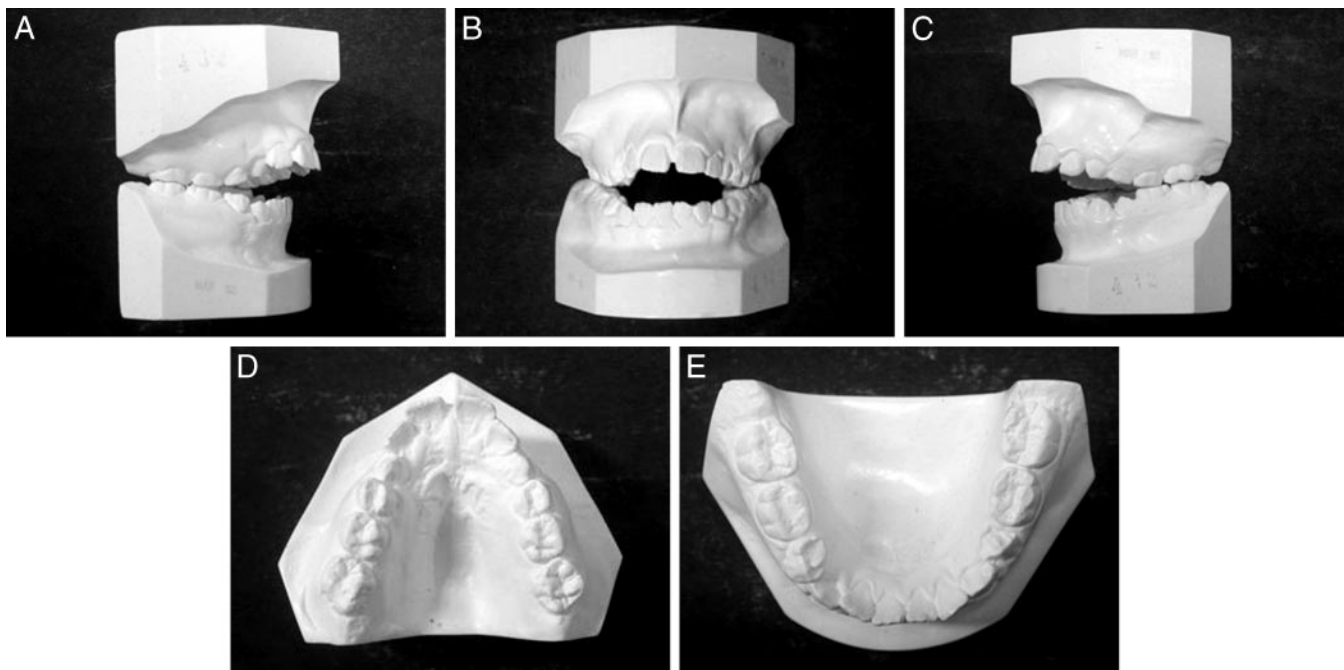
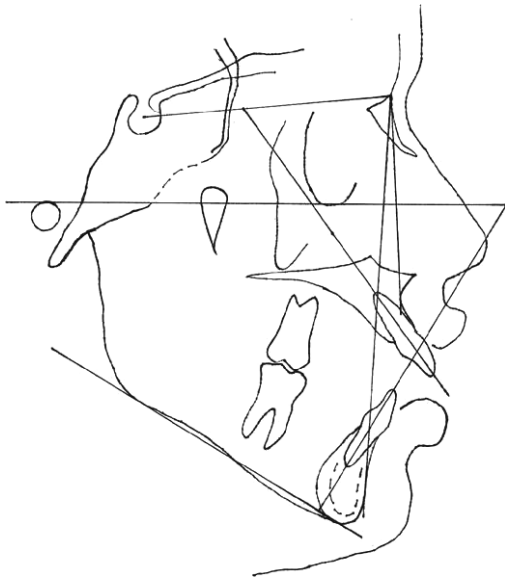


FIGURE 3. Pretreatment study casts.

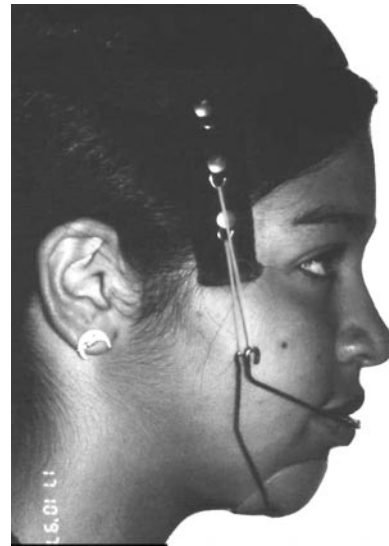

**FIGURE 4.** Pretreatment cephalometric tracing.

### Treatment alternatives

On the basis of the skeletal discrepancies, an orthognathic surgical treatment was discussed, but the parents deemed it too aggressive and selected an immediate treatment option without the need to wait for many years until the end of the jaw growth period. Thus, a nonsurgical plan was devised to close the open bite and alleviate the patient's chief complaint.

A two-phase treatment was selected. In the early intervention, a fixed tongue crib, a Haas-type palatal expander, and a modified high-pull maxillary splint were prescribed. To improve the facial profile in the second phase of treatment, the Class II malocclusion would be corrected by extracting the maxillary and mandibular first premolars and using a high-pull headgear to reinforce anchorage during incisor retraction. Prevention of molar extrusion and loss of anchorage in the upper arch would be essential for the success of the nonsurgical plan. The patient was told about the



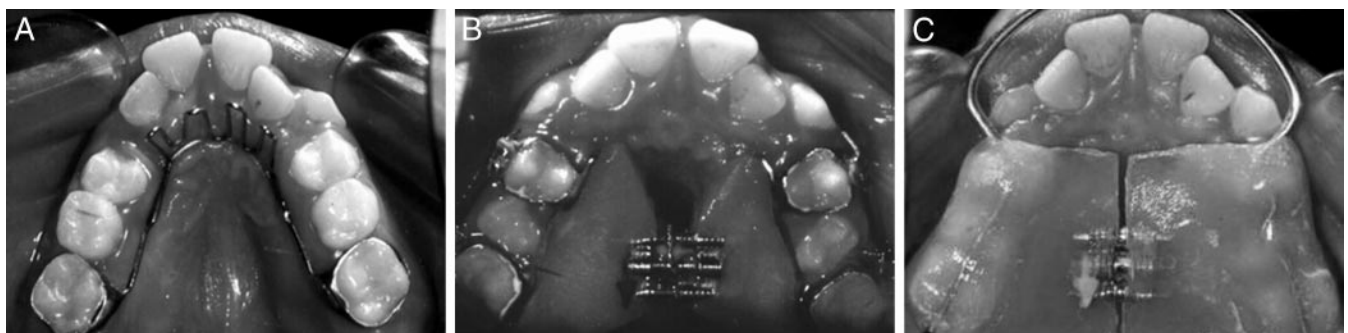
**FIGURE 6.** Facial photograph showing the vertical-pull chin cup concomitant with headgear therapy.

complexity of this plan and about the need for perfect compliance with headgear and vertical elastics.

### Treatment progress

The palatal tongue crib initially was placed extending approximately 2 mm apical to the incisal edges of the mandibular incisors in centric occlusion. The rationale for the tongue crib, which was soldered on the lingual of the molar bands, was to inhibit the anterior tongue thrust and to serve as a reminder against dummy sucking. (Figure 5A)

The palatal crib was removed after 8 months, and a Haas-type expander was used to increase maxillary width (Figure 5B). The patient's mother was instructed to activate the screw two turns per day. To produce a more favorable dental base relationship, the maxillary posterior teeth were markedly overexpanded, and 3 weeks later, activation was discontinued. After 3 months of retention the expander was removed. Four



**FIGURE 5.** The appliances for the first phase of treatment. (A) Palatal crib. (B) Haas-type maxillary expander. (C) Modified high-pull maxillary splint.

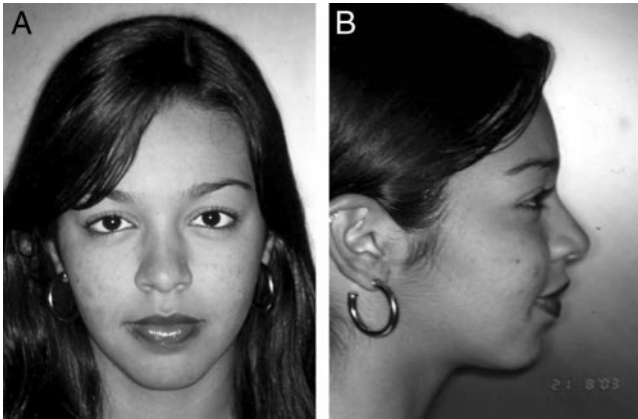

FIGURE 7. Posttreatment facial photographs.

months later, a modified high-pull maxillary splint was initiated (Figure 5C). The patient was instructed to wear the appliance 14 out of every 24 hours. The screw was activated once at each of the next 10 appointments until the first phase was completed. The patient cooperation was good during the 16 months of maxillary splint therapy. The patient was given a Hawley retainer to wear for the next 18 months.

The second phase was initiated with a high-pull headgear with the inner bow expanded. After 4 months of good headgear compliance, a 0.022-inch standard edgewise fixed appliance was placed, and maxillary and mandibular first premolars were extracted. Both arches were leveled, and the canines were retracted with a power chain. Eleven months into fixed treatment, the patient was instructed to wear a vertical chin

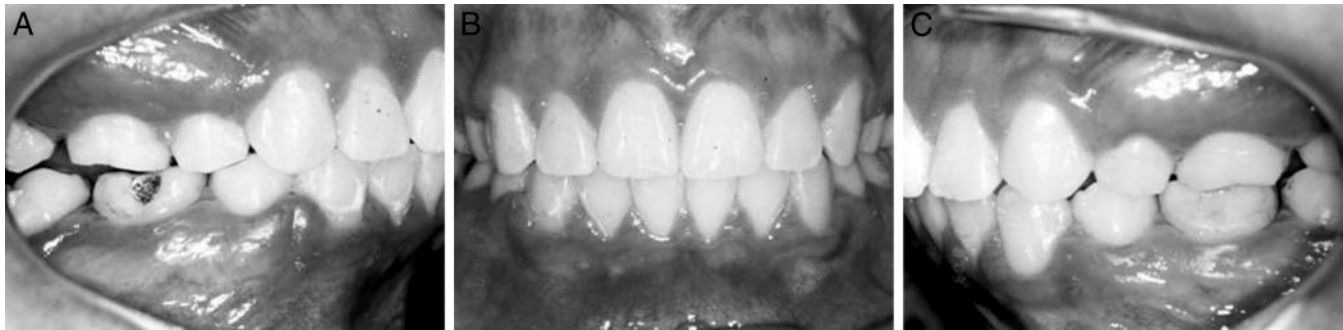

FIGURE 8. Posttreatment intraoral photographs.

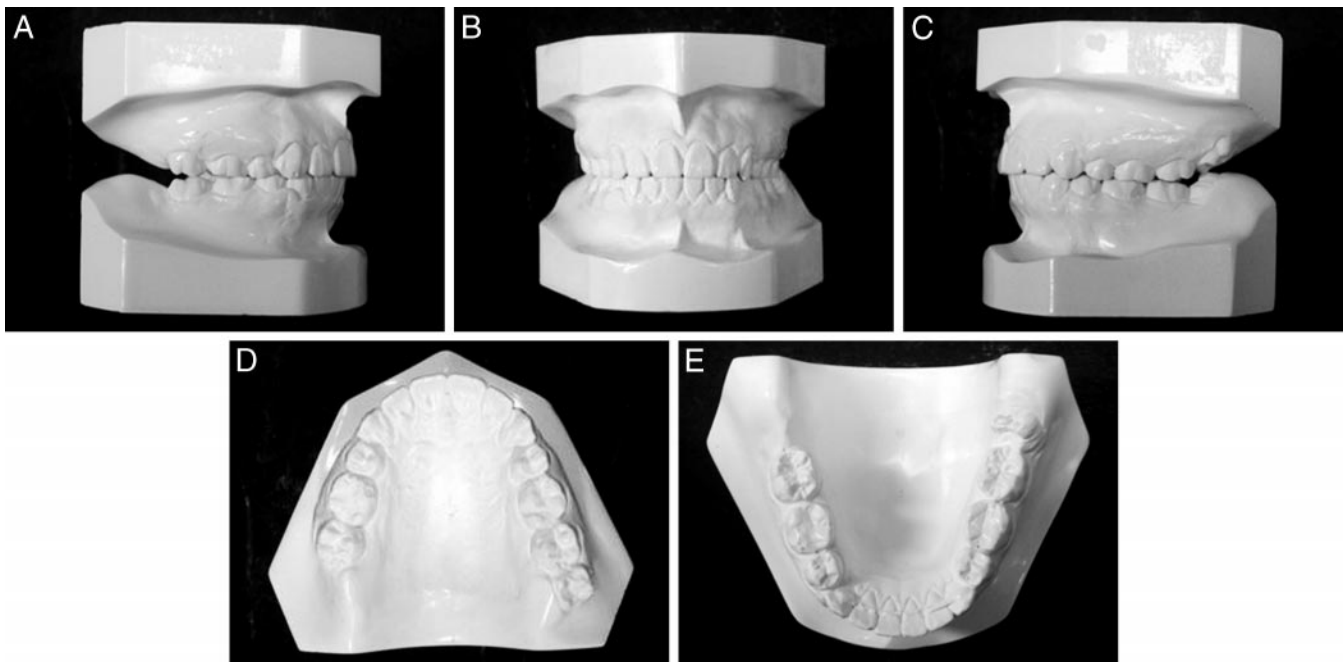


FIGURE 9. Posttreatment study casts.



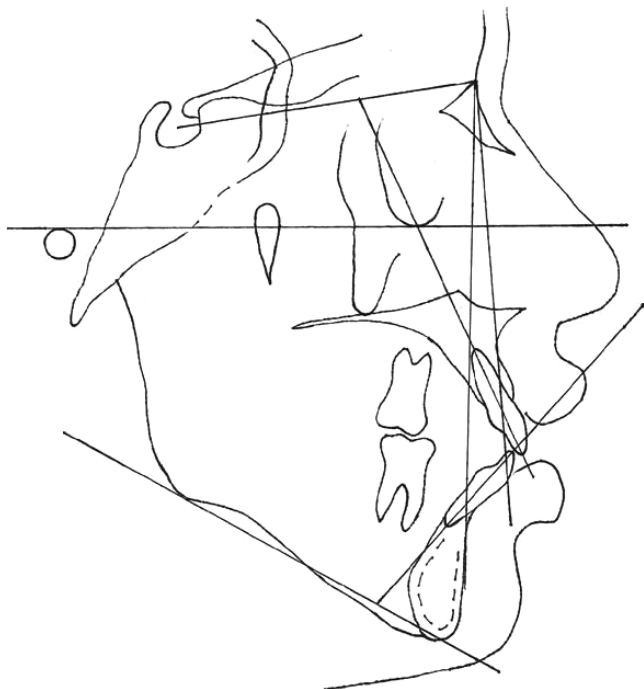


FIGURE 10. Posttreatment cephalometric tracing.

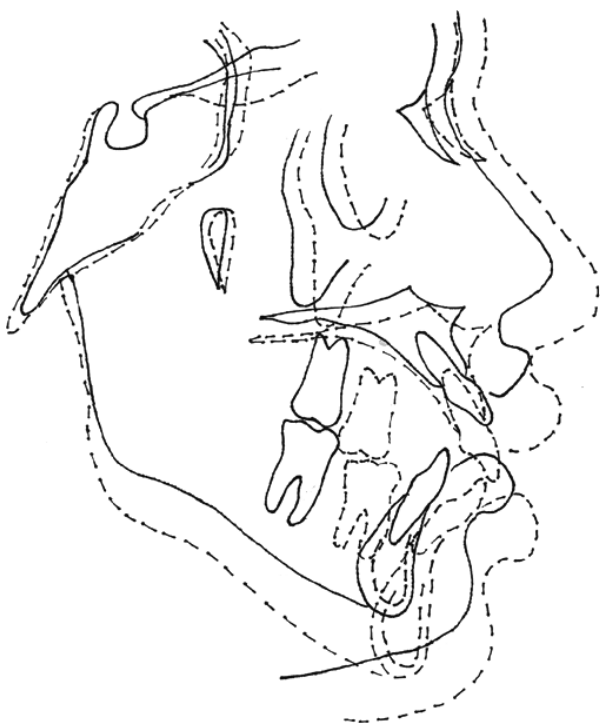


FIGURE 11. Superimposed cephalometric tracings.

cup for 8 hours every night, concomitant with head-gear therapy to improve the closing of anterior open bite (Figure 6). Closing loops (0.019 × 0.025-inch stainless steel upper and lower) were used to consolidate extraction space and retract the incisors.

Twenty-four months after initial bracket placement,

the chin cup therapy was discontinued. A 0.018 × .025-inch stainless steel upper and lower archwire with triangular vertical elastics to the maxillary and mandibular canines and premolars were used to close the bite. There was no compliance in the use of elastics. Thirteen months of treatment were lost, and tip back bends were done to intrude upper molars. Later, the patient agreed to cooperate and a 0.018 × 0.025-inch stainless steel upper archwire with a curve of Spee was placed, and anterior box elastics were introduced. The bite was closed and the archwires were sectioned distal to the canines, and bilateral box elastics from the maxillary canine and first premolar to the mandibular first and second premolars were placed for 6 months. The occlusion was detailed.

For retention, the patient was instructed to wear a maxillary wraparound Hawley retainer 24 hours per day for 2 years and at night for another 6 months. In the mandible, a canine-to-canine retainer was bonded. Because of the potential for return of the open bite during the retention phase, the patient was highly motivated to comply with daily tongue exercises.

## RESULTS

Considering the skeletal pattern and nonsurgical approach that was chosen, excellent facial and occlusal results were achieved despite lack of patient cooperation in the second phase of treatment. Posttreatment photographs and study casts (Figures 7–9) show bilateral Class I molar and canine relationships and ideal overjet and overbite. At the completion of treatment, the lips were slightly less protrusive with improved lip competence.

Cephalometric analysis and superimpositions showed that both the maxilla and mandible showed anterior growth (Figures 10 and 11). The maxillary molars were protracted, whereas the maxillary incisors were retracted and extruded. The mandibular molars were protracted and extruded, whereas the incisors were retracted and extruded. The lower anterior face height, SN-GoGn angle, Frankfort mandibular plane angle, and y-axis to SN angle, all remained stable (Table 1).

Evidence of minimum to moderate generalized root resorption was present radiographically after approximately 8 years of active two-phase treatment. Occlusally, the maxillary molars were not completely seated at the debanding appointment, the open bite was closed, and good intercuspation was achieved. The periodontium remained healthy, and the temporomandibular joints were asymptomatic.

## DISCUSSION

Faced with the limitations of orthodontic treatment, most orthodontists would agree that this type of case

**TABLE 1.** Summary of Cephalometric Analysis

	Standard	Pretreatment	Posttreatment
SNA (°)	82	88	86
SNB (°)	80	82	80
ANB (°)	2	6	6
FMA (°)	25	30	29
Y-axis to SN (°)	59.4	62	61
SN-GoGn (°)	32	36	37
1/NA (°)	22	32	19
1-NA (mm)	4	8	7.5
1/NB (°)	25	28	39
1-NB (mm)	4	5.5	11
1/1 (°)	131	113	114
IMPA (°)	93	90	101

is ideally treated with a combination of orthodontics and orthognathic surgery.<sup>7</sup> The advantages of the orthognathic surgical treatment are that the overbite can be overcorrected and posttreatment stability is better than that with a nonsurgical option.<sup>8</sup>

In Brazil, most patients do not readily accept orthognathic surgery. For this reason, orthodontic correction of the functional and morphological problems that affect the patient's psychology at an early stage could have a beneficial effect on general personality development.<sup>9</sup>

In a nonsurgical plan, the orthodontist camouflages the skeletal discrepancies to an extent that satisfies as many of the patient's esthetic and functional concerns as possible. The patient must be told that the nonsurgical correction usually requires a longer treatment time and is more difficult, especially for stability and retention.<sup>7</sup> In this case, the nonsurgical correction of the anterior open bite included a high-pull headgear appliance, a vertical-pull chin cup, dental extractions, and anterior vertical elastics.

The high-pull headgear appliance was used to intrude the maxillary posterior teeth.<sup>10-12</sup> Its use was limited because the forces were applied to the maxilla with no direct treatment effects on mandibular shape or growth. The vertical-pull chin cup was successfully used to control excessive lower anterior face height and helped to prevent extrusion of posterior teeth.<sup>13-15</sup> The bicuspid extraction aided in bite closure and was associated with precision and accurate mechanics.<sup>16</sup> Finally, anterior vertical elastics were used to extrude the maxillary and mandibular incisors and to close the remaining open bite.

The final outcome of the treatment was a great improvement in function and esthetics, although the stability of the open-bite closure is questionable. The

main reason this patient could be successfully treated nonsurgically was her initial compliance and the arsenal of therapy options used during approximately 8 years of two-phase treatment.

At retention, a check 12 months after removing appliances, the occlusion remained stable. However, long-term control will be needed because open-bite malocclusions treated nonsurgically tend to relapse more than most other types of malocclusions.

## REFERENCES

1. Subtelny JD, Sakuda M. Open-bite: diagnosis and treatment. *Am J Orthod.* 1964;50:337-358.
2. Alexander CD. Open bite, dental alveolar protusion, Class I malocclusion: a successful treatment result. *Am J Orthod Dentofacial Orthop.* 1999;116:494-500.
3. Kim YH. Anterior open bite and its treatment with multiloop edgewise archwire. *Angle Orthod.* 1987;57:290-321.
4. Hotokezaka H, Matsuo T, Nakagawa M, Mizuno A, Kobayashi K. Severe dental openbite malocclusion with tongue reduction after orthodontic treatment. *Angle Orthod.* 2001;71:228-236.
5. Epker BN, Fish LC. Surgical-orthodontic correction of open-bite deformity. *Am J Orthod.* 1977;71:278-299.
6. Woods MG, Nanda RS. Intrusion of posterior teeth with magnets. An experiment in growing baboons. *Angle Orthod.* 1988;58:136-150.
7. Hiller ME. Nonsurgical correction of Class II open bite malocclusion in an adult patient. *Am J Orthod Dentofacial Orthop.* 2002;122:210-216.
8. Denison TF, Kokich VG, Shapiro PA. Stability of maxillary surgery in open bite versus non-open bite malocclusions. *Angle Orthod.* 1989;59:5-10.
9. Kondo E, Aoba TJ. Nonsurgical and nonextraction treatment of skeletal Class III open bite: its long term stability. *Am J Orthod Dentofacial Orthop.* 2000;117:267-287.
10. Baumrind S, Molthen R, West E. Mandibular plane changes during maxillary retraction. *Am J Orthod.* 1978;74:32-40.
11. Watson W. A computerized appraisal of the high-pull facebow. *Am J Orthod.* 1962;62:561-578.
12. Firouz M, Zernik J, Nanda R. Dental and orthopedic effects of high-pull headgear in treatment of Class II, division I malocclusion. *Am J Orthod Dentofacial Orthop.* 1992;102:197-205.
13. Lindsey CA, English JD. Orthodontic treatment and masticatory muscle exercises to correct a Class I open bite in an adult patient. *Am J Orthod Dentofacial Orthop.* 2003;124:91-98.
14. Pearson L. Vertical control in treatment of patients having backward-rotational growth tendencies. *Angle Orthod.* 1978;48:132-140.
15. Pearson L. Case report KP. Treatment of a severe openbite excessive vertical pattern with an eclectic non-surgical approach. *Angle Orthod.* 1991;61:71-76.
16. Kuroda S, Katayama A, Takano-Yamamoto T. Severe anterior open-bite case treated using titanium screw anchorage. *Angle Orthod.* 2004;74:558-567.